

GKS 13.10.2011
Eero Varila, MD

INTIMATE SURGERY

- INDICATIONS

Ambiguous terminology

- Intimate gynecological surgery
- Gynecological cosmetic surgery
- Aesthetical gynecological surgery
- Surgical repair



Cosmetics or medicine?

- Few scientific researches
 - Mostly retrospective interview investigations
- Inappropriate marketing
 - "Designer Vaginas, Perfect Vagina, G-spot Augmentation"
 - Unrealistic body image

LabiaplastySurgeon.com

... discreet and confidential help for women



Lack of education

- Assessment of indications
- Inadequate technic
- Difficulties to have an objective view on the topic
- The real problems may not be treated

Intimate Surgery

- Labiaplasty
- Vulvoplasty
- Perineoplasty
- Hymen repair
- Episiotomy scar repair
- Liposuction
- Vestibulectomy

Reasons

- Physical disorders
 - Pain
 - Rub
 - Irritation
 - Laxity
 - Vaginal wind
- Aesthetical disorders
 - Labial hypertrophy
 - Scars
- Social indication
 - Non-virging hymen
- Purely cosmetic reasons

To treat or not to treat?

- Patient's symptoms and expectations
 - Real symptoms or unrealistic body image?
- Physician's opinion
 - Clinical status
 - Normal or abnormal
 - Severity of the symptoms
 - Benefits and risks of the treatment
 - Treatment alternatives

To treat or not to treat?

- ✧ Treatment must be based on a real indication
 - ✧ Don't underestimate the patient
 - ✧ "Just for fun" is not an indication
- ✧ Don't use surgery when it's not indicated
 - ✧ Explain and argue carefully why not
- ✧ Consultation of an other specialist
 - ✧ Psychologist
 - ✧ Physician

Hyperplasia labiae minora

Indication: functional or aesthetic ?

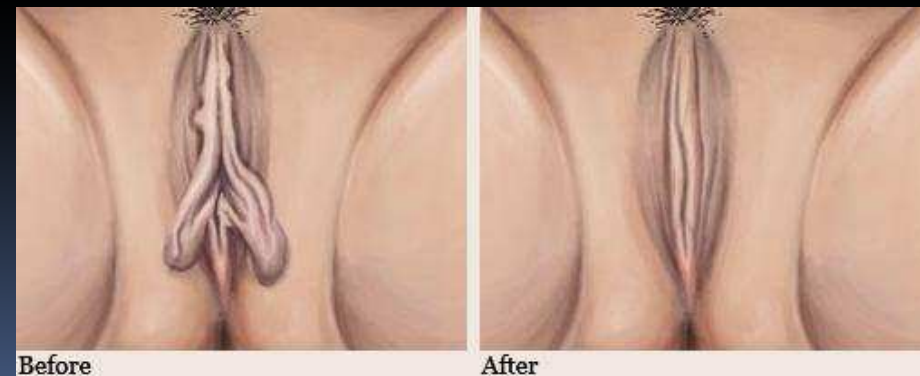Miklos et Moore 2008. Labiaplasty of the Labia Minora: Patients' Indications for Pursuing Surgery. The Journal of Sexual Medicine

N 131

- | | |
|-----------------------------------|-----|
| □ Physical symptom only | 32% |
| □ Functional and Aesthetic reason | 31% |
| □ Aesthetic reason only | 37% |

No consensus of the normal size of the labia minora

- Radman 1976 5 cm
- Rouzier et al. 2000 4 cm
- Pardo et al. 2006 <4 cm



Gambar 2. Pre-op dan post-op vaginal rejuvenation

Labiaplasty

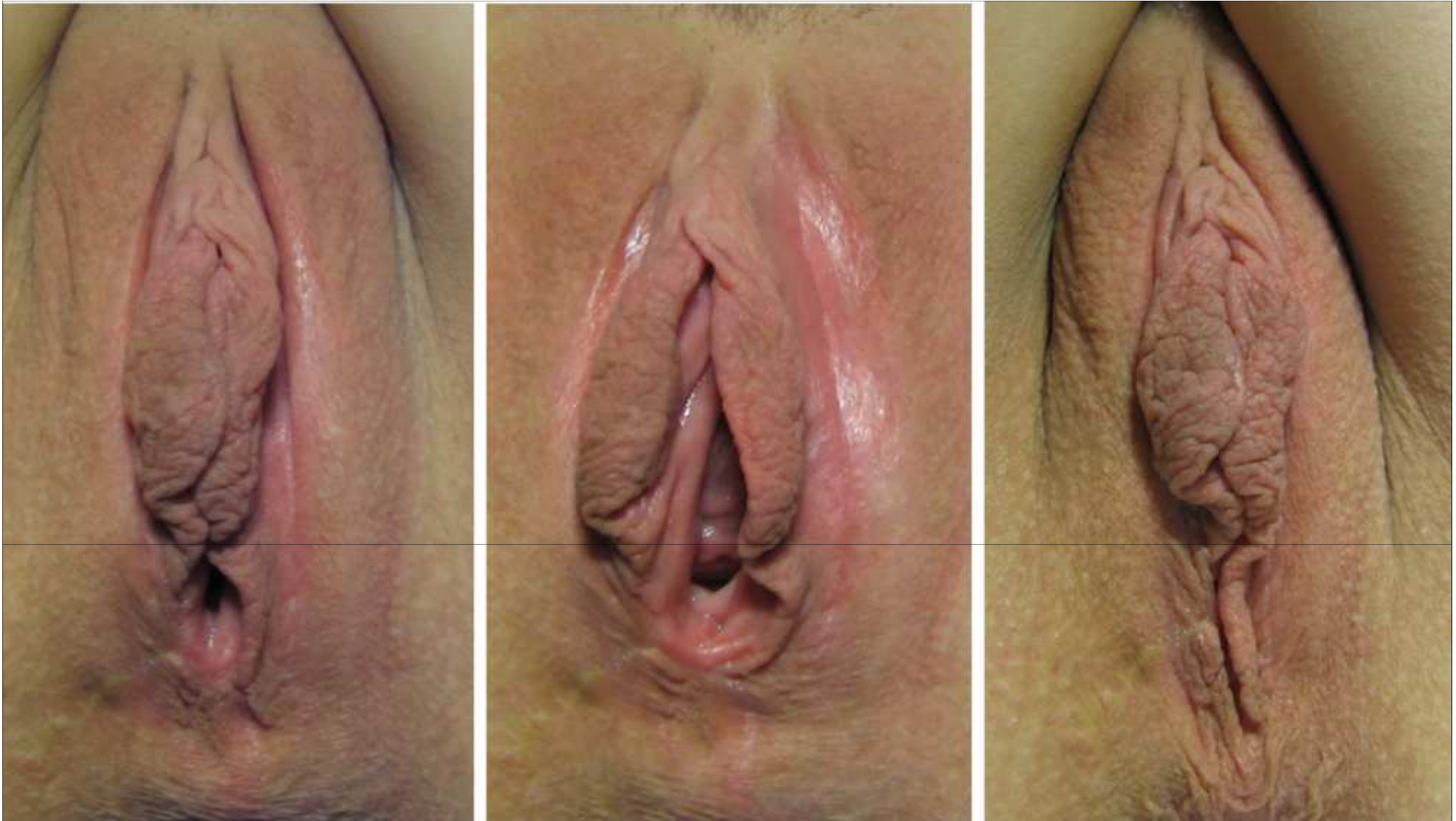- Complications

- Labial asymmetry
- Poor wound-healing
- Under-correction, over-correction
- Neural irritation

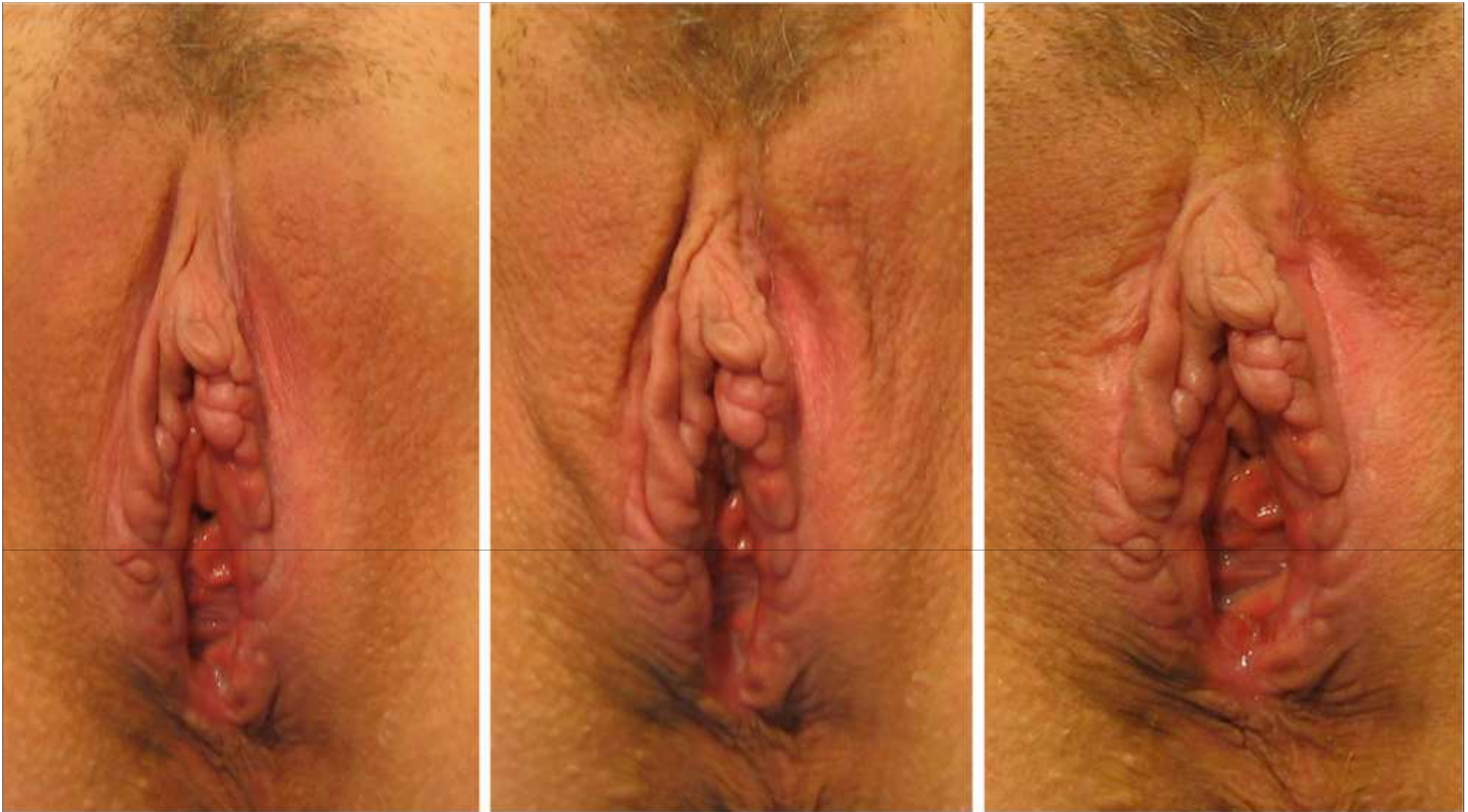- 9 years follow-up

- Satisfied with functional result 93%
- Satisfied with aesthetic result 89%

Rouzier et al. Am.J Obstet.Gynecol. 2000

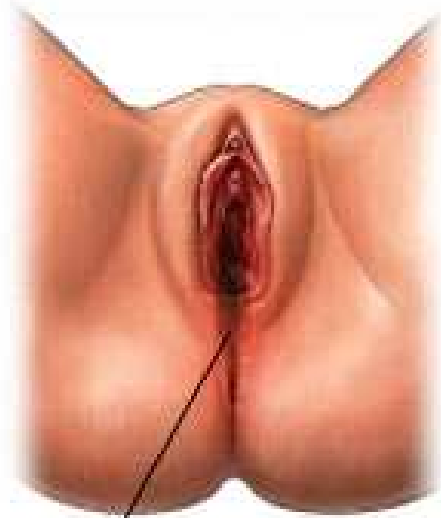

Ennen leikkausta

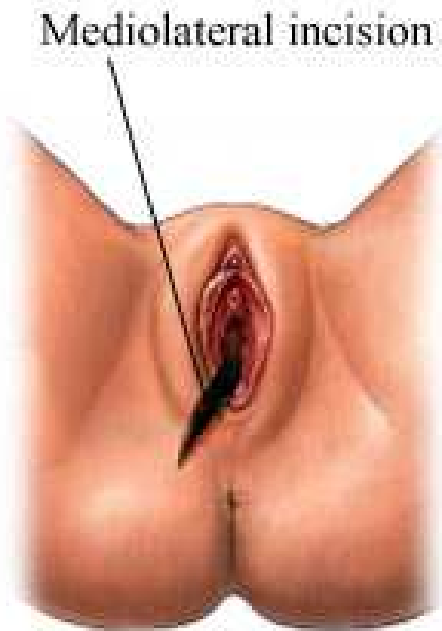

Leikkauspäivä 23.11 - 2010
Valokuva 30.12 - 2010

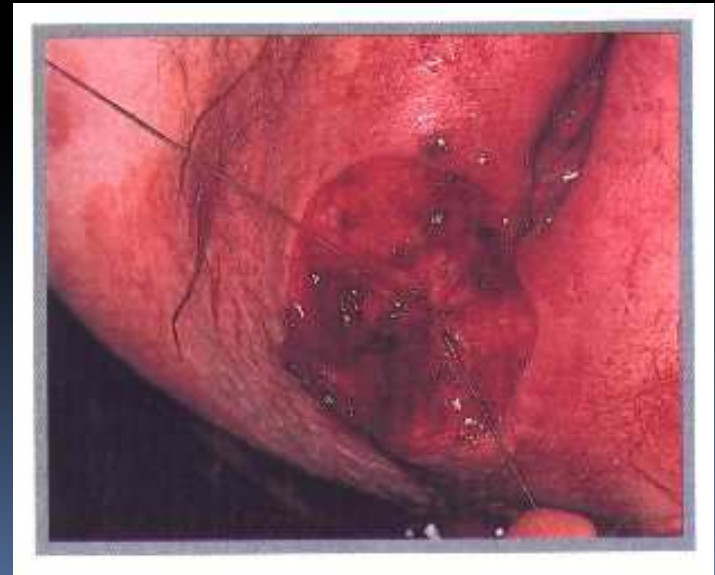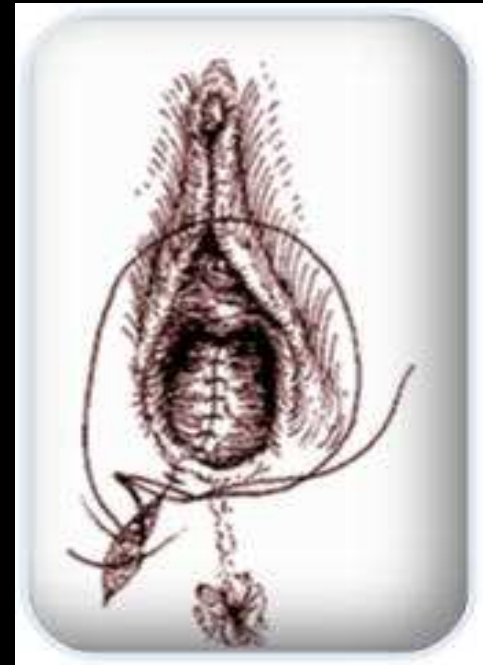
Episiotomy scar repair



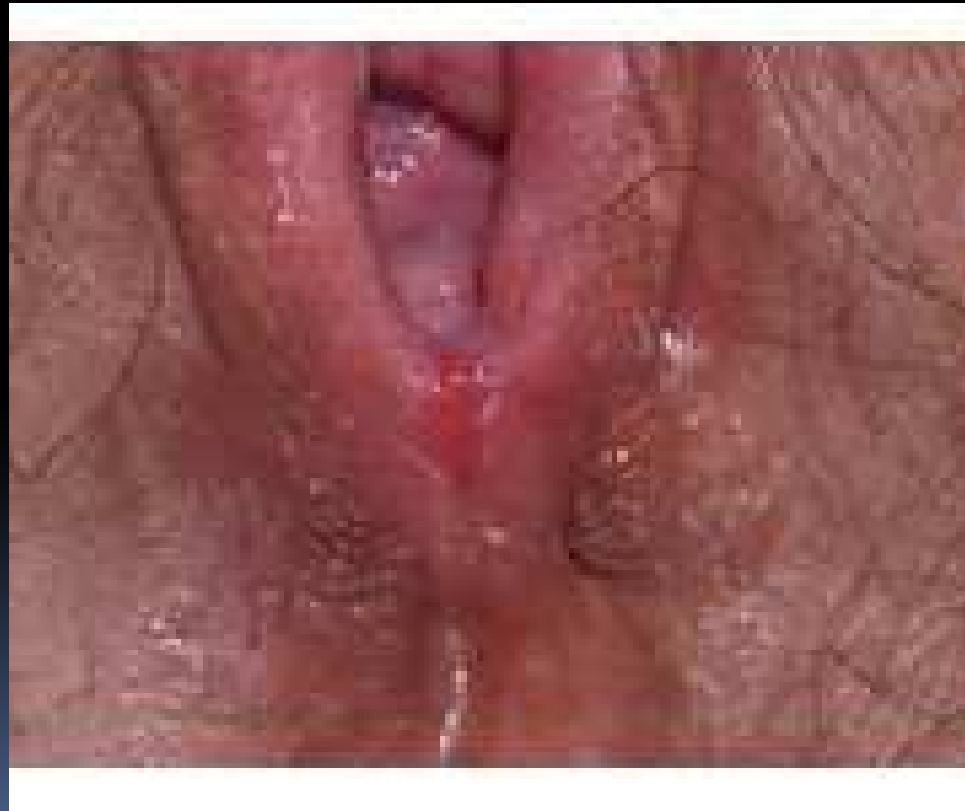Midline incision



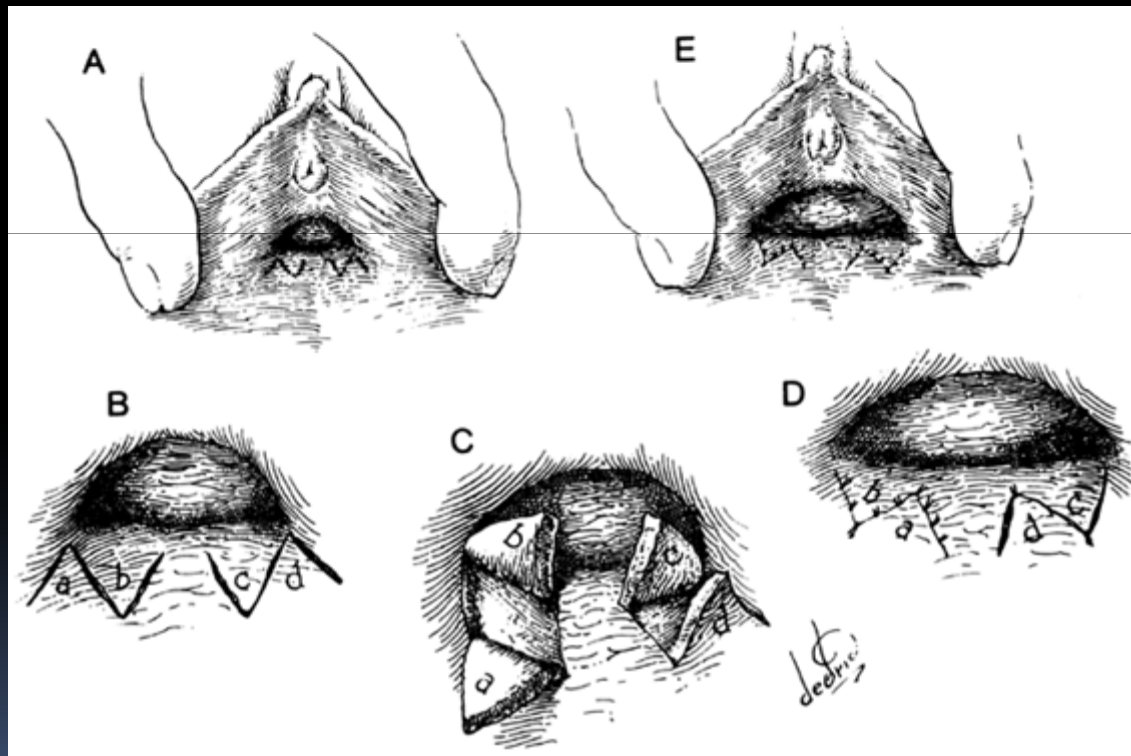
Mediolateral incision



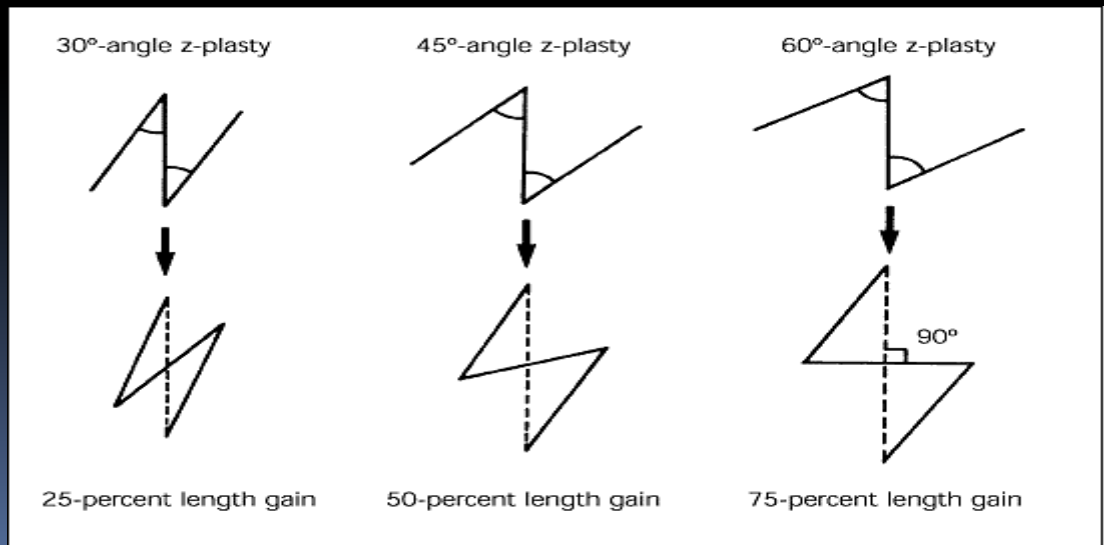
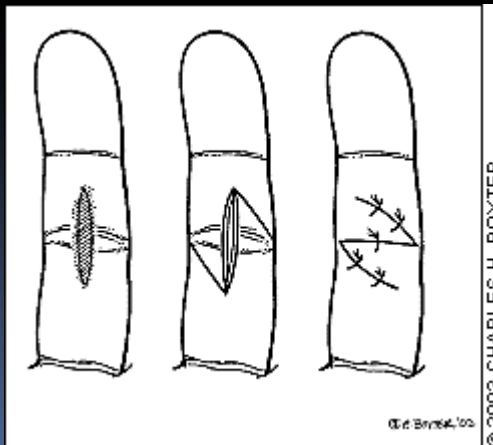
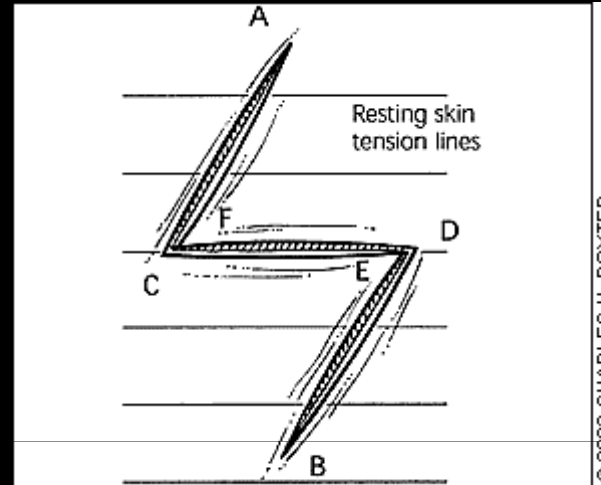
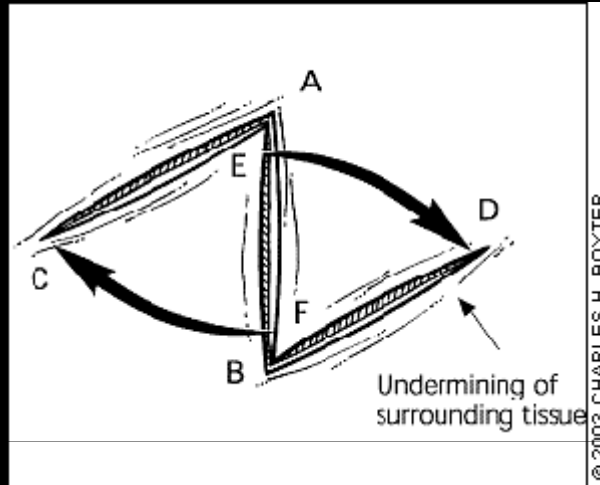
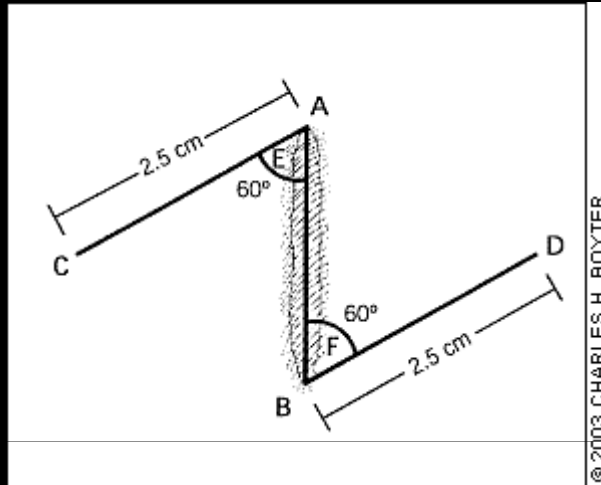
Fissure, laceration Vulvar fold



W-plasty



Z-plasty

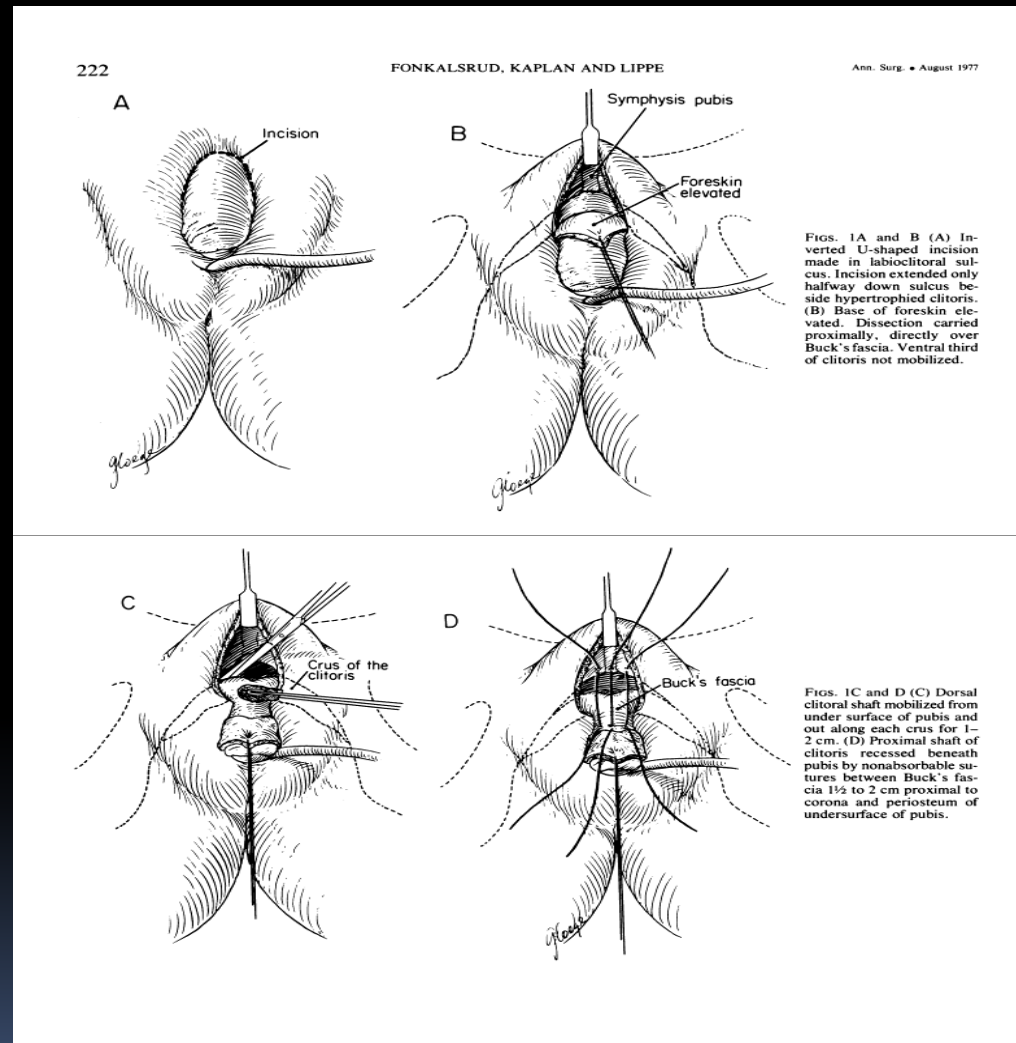


Vaginal laxity

- Symptoms
 - sexual dysfunction
 - vaginal wind
 - Irritation
- “When a multidisciplinary, conservative approach fails, surgical intervention may be justified. Recent publications suggest some benefits to sexual function.”

Cardozo L. 2008

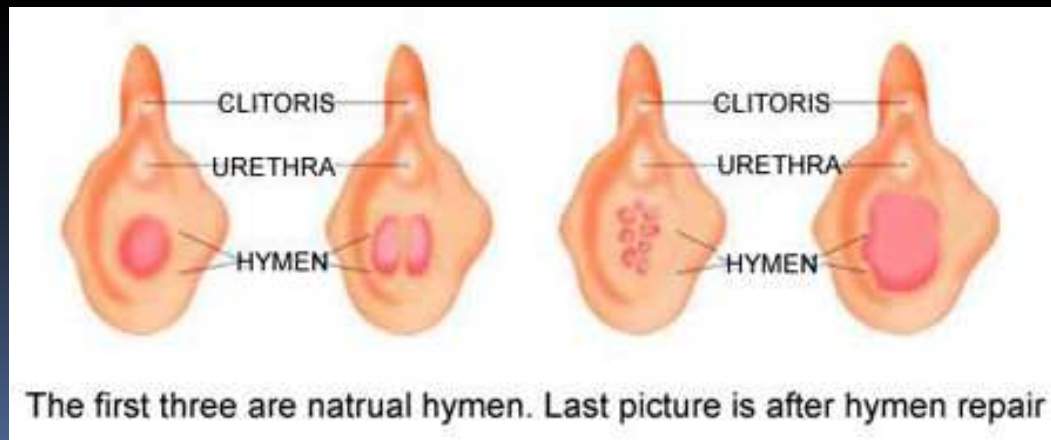
Reduction clitoroplasty for clitoral hypertrophy



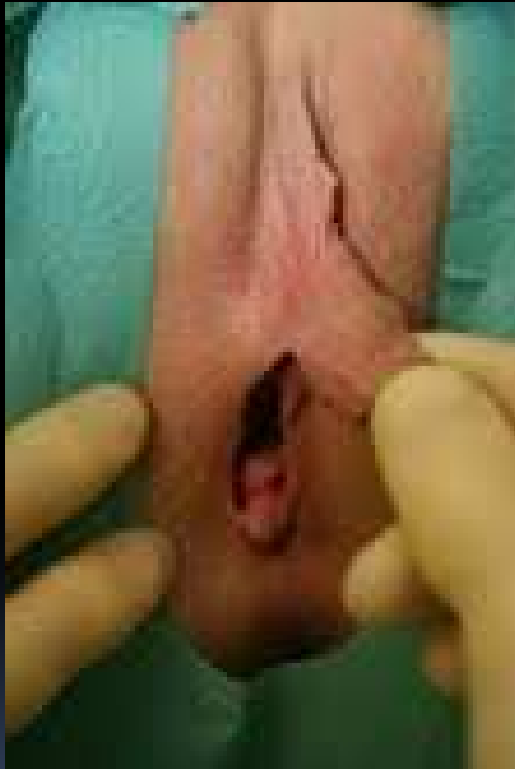E W Fonkalsrud, S Kaplan, and B Lippe Ann Surg. 1977 August; 186(2): 221–226.

Hymen

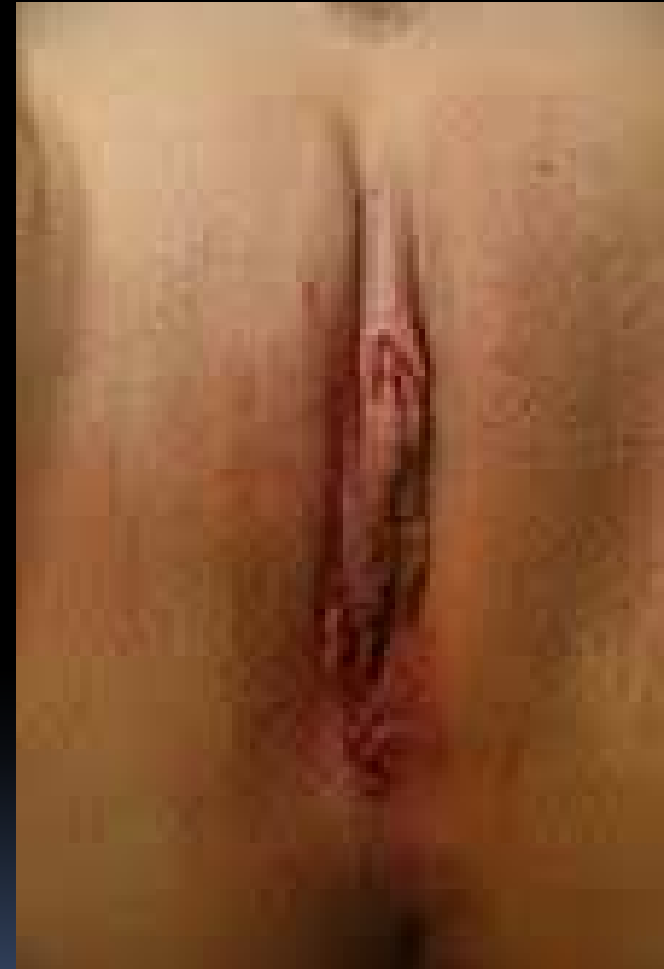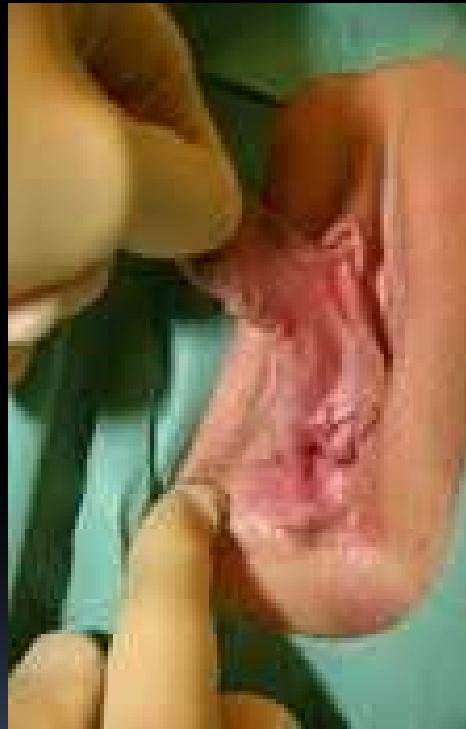- Hymen repair (revirgination)
- Easy, no complications
- But...
 - Is it justified because of purely social indication?



Repair after post operative laceration



Before



After repair

Indications and benefits - careful assessment

“ACOG Advises Against Cosmetic Vaginal Procedures Due to Lack of Safety and Efficacy Data.”

ACOG Committee Opinion. Vaginal “rejuvenation” and cosmetic vaginal procedures. *Obstet Gynecol* 2007;110:137-38.

“The results may not always meet the expectations of the patient or the physician.”

The Department of Health in the UK

Challenges in Finland

Recognition of the real symptoms

Assessment of indications

Surgical technic

Appropriate marketing